



GLOBAL JOURNAL OF ADVANCED RESEARCH  
(Scholarly Peer Review Publishing System)

## SIGNIFICANCE OF WORKING LENGTH IN RCT: A CASE REPORT

### Dr Priyanka Bhushan

MDS Public Health Dentistry,  
Asst Prof RIMS Dental College,  
Lamphelpat, Imphal,  
India  
[drpiyu24@yahoo.co.in](mailto:drpiyu24@yahoo.co.in)

### Maj Kundan Kumar

BDS Army Dental Cops,  
OC, 1204 Dental Unit,  
C/O 99 APO,  
India  
[kundankr3080@gmail.com](mailto:kundankr3080@gmail.com)

### Dr Tanya Nandkeoliar

MDS Periodontics,  
Asst Prof, RIMS Dental College,  
Lamphelpat, Imphal,  
India  
[tanya.nandkeoliar@gmail.com](mailto:tanya.nandkeoliar@gmail.com)

### ABSTRACT

Root Canal Treatment is the desired treatment of choice where the functionality and integrity of the natural tooth is to be preserved. Inadequate obturations, insufficient cleaning, unfilled and untreated root space, under or over obturation due to improper measurements of working length are the main causes of endodontic treatment failure. In normal instances and cases working length is measured from specific coronal portion to minor diameter or apical constriction till where the instrumentation and obturation should end. There are three most widely accepted methods for measurement of working length namely radiographic method, Apex locators and tactile perception. Studies have shown an accuracy of 86.7% was obtained within 0.5 mm of the canal length while determining working length with the apex locators. However determining working length by radiographic method is equally accurate for small dental centres located at interior areas where apex locators are not available.

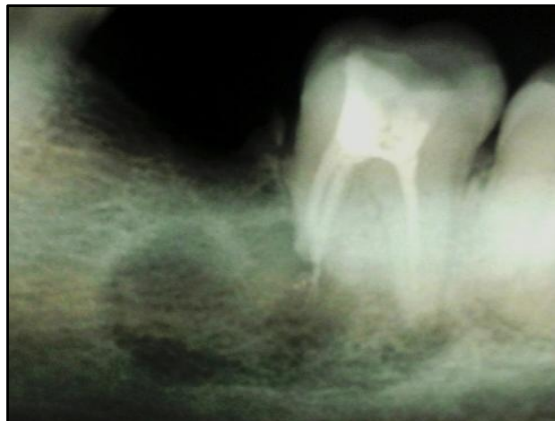
### Keywords

RCT, Working Length, Radiograph, Obturation.

### 1. INTRODUCTION

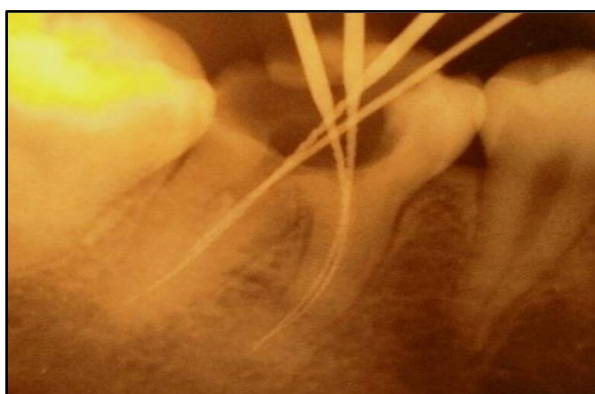
Root Canal Treatment is the desired treatment of choice where the functionality and integrity of the natural tooth is to be preserved. Endodontic therapy or RCT is a complex and multiple process technique which includes access cavity preparation, location and establishing the patency of root canals, working length determination, pulp extirpation, biomechanical preparation, obturation and restoration of damaged tooth portion. The aim of RCT is elimination and removal of microbial infection of the canals of the tooth and to prevent reinfection by obtaining a tight seal of root canal space.

As RCT involves multiple process to pinpoint one particular reason for failure of RCT is very difficult. However various studies conducted to ascertain the reasons for failure of RCT shows the main causes of endodontic failure making retreatment necessary is insufficient cleaning and inadequate obturation (1). Together with this unfilled or untreated root canal, under extended or over extended root fillings due to improper measurement of working length are some of the other main reasons for failure of RCT (Fig 1).



**Figure 1 Radiograph of RCT of 47 showing Over-obturation and Periapical Lesion**

Studies have demonstrated that part of the root canal spaces often didn't prepared during biomechanical preparation may contain bacteria and necrotic tissue that may result eventually in root canal failure (2). So measurement of exact working length of the tooth is one of the most important steps in endodontic process Fig 2.



**Figure 2 Working Length Radiograph of 36 Teeth**

Inaccurate determination of working length may lead to short or overextended obturation. Short working length may result in retained necrotic tissues in apical area and overextended working length may result in over-instrumentation and over-obturation.

## **2. METHODS OF MEASURING WORKING LENGTH**

According to American Association of Endodontics 2003, Working Length is defined as 'the distance from a coronal reference point to the point at which the canal preparation and filling should terminate' (3). In normal instances and cases working length is measured from specific coronal portion to minor diameter or apical constriction till where the instrumentation and obturation should end. Apical constriction is located 0.5-0.75 mm coronal to the Major foramen which in turn is located 0.5mm coronal to the apical terminus (3, 4). Currently, the three accepted methods for determining working length are (a) radiographs (b) electronic apex locators, and (c) the paper point method (5).

### **2.1 Radiographic Method**

Described by Ingle is one of the most common and reliable method used for working length determination. Radiographs are important in endodontic process to access canal curvature, root form, calcification etc; however radiographs have limitations to working length determination. Identifying the apical constriction is difficult, together with variables in techniques; angulations and exposure distort the image and lead to error in working length due to laterally situated foramina (6).

### **2.2 Electronic Apex Locator**

Working length determination by electronic method was first done by Custer in 1918 (7). Suzuki in 1942 first developed electronic apex locator (8). This device was resistance based and measured the resistance between two electrodes. Later devices were impedance-



based (9). Apex locators measure the change in electrical impedance at the canal terminus. This is the reason that they are most accurate at showing when a file is in the canal (not patent) and when a file is out of the canal (patent). The location at which these two points meet is the point of patency, or the canal terminus. This measurement is the true canal length (5). But its accuracy is influenced by electrical condition of the canal and it is inaccurate in teeth with wide-open apex and calcified canals.

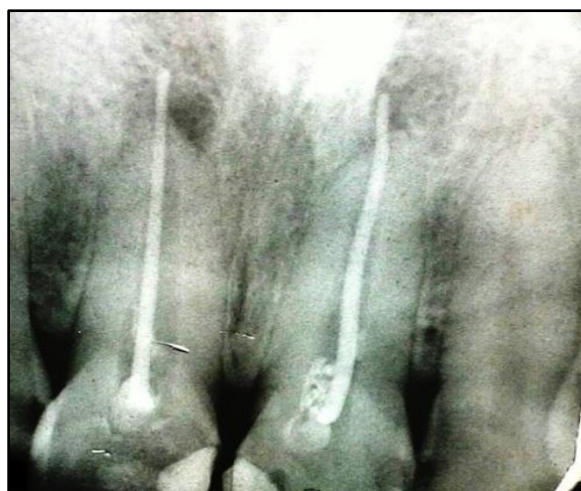### 2.3 Paper point method

Is employed before the obturation and requires a shaped canal following instrumentation. A feather-tipped paper point is placed through the terminus of a dry patent canal. The tip of the paper point becomes moist where it exits the canal and bends easily and the moisture spot is the true working length for obturation (5).

The **Tactile Perception** because of the simplicity of the technique and its virtual effectiveness are factors that motivate a few clinicians in endodontic practice to still follow this technique (10). It entirely depends on the experience of the clinician who places the file in the canal and depending on the resistance determines the canal length. But this technique is in general inaccurate in root canals with immature apex, excessive curvature and if the canal is constricted throughout its length.

### 3. CASE REPORT

25 yr old patient reported to dental centre located at interior area of Aizawl Mizoram State with chief complain of pain and tenderness in upper anterior region. Patient had undergone RCT of 11 & 21 about a year back. Patient was advised to undergo IOPA radiograph of upper anterior region (Fig 3) which revealed single cone overobturation of 11 & 21 leading to periapical lesion.

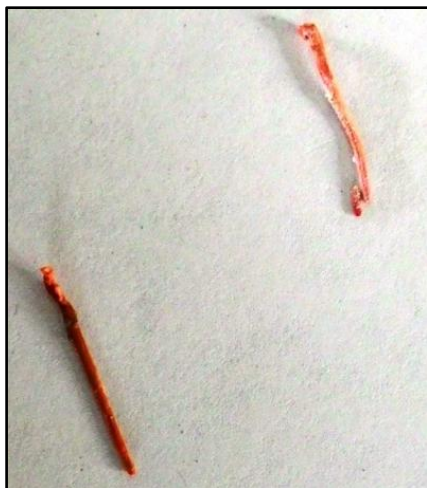

**Figure 3 Radiograph of RCT Treated 11, 21 Tooth**

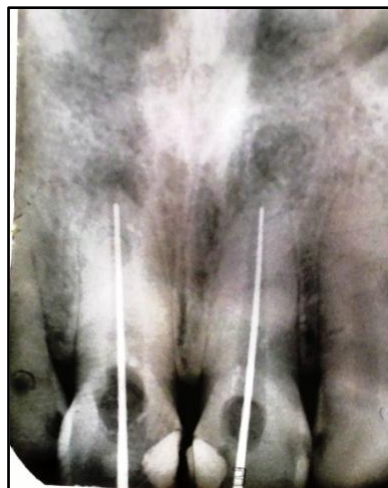After undergoing RCT patient was advised to undergo crown in relation to 11, 21 but due to cost factor patient had not got the crown fabricated.

Since single cone gutta percha was used for obturation and the fact that patient had not got the crown fabricated made the retreatment option much easier. Access cavity was again prepared and the single cone gutta percha was removed in single attempt with the help of broach and H file (Fig 4).

Being a small government dental centre located in the interior area Apex locator is not authorized and the same was not available with the dentist. So the radiographic method was employed to determine the working length of 11, 21 (Fig 5).



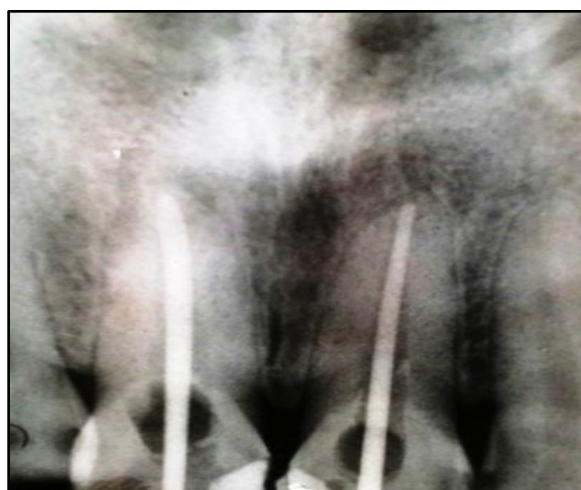
**Figure 4 Single Cone Gutta Percha Removed from the Root Canal**



**Figure 5 Working Length Radiograph of 11, 21**

After working length determination biomechanical preparation was done to remove any necrotic tissue left in the canal. Closed dressing was given and patient recalled after 2 days.

Patient was completely asymptomatic after closed dressing and hence obturation was planned. But due to over instrumentation especially in relation to 11 tooth even the 80 No. GP was crossing the apex so had to be suitably cut to fit at the apex whereas 60 N. GP was used in 21 for obturation. A preobturation radiograph was taken (Fig 6) which showed the GP snugly fitting at the apex with slight tug back force required to remove it from canal.



**Fig 6 Pre Obturation Radiograph of 11, 21**

After obturation was done and access cavity restored patient was asked to undergo crown preparation.

#### **4. DISCUSSION**

Complete removal of necrotic tissue from the root canal and its filling till the apical foramen is essential for successful endodontic treatment. In a study conducted by Nouman Noor and colleague to access the reasons for RCT failure showed most of the cases failed because of inadequate root canal filling such as untreated or unfilled root canals, under extended root canal fillings and poor lateral condensation and over extended root canal filling (11). Chugal and colleagues reported that a 1-mm loss in working length increased the chance of treatment failure by 14 percent in teeth with apical periodontitis (12). Under filling does not have a direct effect on the outcome of endodontic therapy; rather, it is the remaining infected necrotic tissue in the inadequately instrumented and incompletely



filled canal that causes continuing irritation to the periradicular tissues (12). Most of the under filling or over filling of the canal occurs due to inadequate measurement of the working length of the tooth. Most of the dental doctors overlook the importance of working length and rely heavily on tactile perception to determine the working length. Working Length determined by apex locators give the most accurate working length of the root canal. Study conducted by Muthu Shanmugaraj and colleague showed an accuracy of 86.7% was obtained within 0.5 mm of the canal length (10) with the apex locators. The advantages of apex locators are that they are supposedly accurate, easy, and fast and reduce exposure to radiation. Artificial perforation can be recognized and it is the only method that can measure length to the apical foramen and not the radiographic apex. The disadvantages are that it requires a special device and accuracy is influenced by electrical condition of canal (13).

## 5. CONCLUSION

It can be concluded that radiographic method to determine working length of root canal is equally accurate method performed under standard specification especially at dental centers located at far flung area with that of apex locator. However were ever possible both diagnostic radiograph and apex locator should be employed for determination of correct working length.

## 6. ACKNOWLEDGEMENT

I would like to thank all the para dental staff of 1204 Dental unit especially Hav/DORA N K Singh for their assistance and help.

## 7. REFERENCE

- [1] Siqueria JF. Etiology of Root Canal Treatment Failure: Why Well Treated Teeth can Fail. *Int Endod J* 2001; 34: 1-11.
- [2] Siqueria JF, Araujo MCP, Garua PF, Fraga RC, Sabota Dantas CJ. Histological Evaluation of the Effectiveness of Five Instrumentation Techniques for cleaning the apical Third Root Canals. *J Endodont* 1997; 23: 499-502.
- [3] Glossary of endodontic terms. 7th ed. Chicago: American Association of Endodontists. 2003.
- [4] Green D. Stereomicroscopic study of 700 Root Apices of Maxillary and Mandibular Posterior Teeth. *Oral. Surg. Oral. Med. Oral. Pathol.* 1960 Jun; 13: 728-733.
- [5] Dr Chris J. Lampert. Determining working length. *Roots* 2012, 3: 26-27.
- [6] Katz A, Tamse A, Kaufman Y. Tooth length determination: A review. *Oral Surg Oral Med Oral Pathol Oral Radiol Endod* 1991; 72:238-42.
- [7] Custer LE. Exact methods of locating the apical foramen. *J. Natl. Dent. Assoc.* 1918; 5: 815-819.
- [8] Suzuki K. Experimental Study on Iontophoresis. *J. Jap. Stomatol.* 1942; 16: 411.
- [9] Nekoofar MN, Ghandi MM, Hayes SJ, Dummer PMH. The fundamental operating principles of electronic root canal length measurement devices. *International Endodontic Journal.* 2006; 39: 595-609.
- [10] Muthu Shanmugaraj, Rajendran Nivedha, Rajan Mathan, Sundaresan Balagopal. Evaluation of working length determination methods: An in Vivo / Ex Vivo Study. *Indian J Dent Res*, 18(2), 2007; 60 – 62
- [11] Nouman Noor, Anser Maxood, Khurram Kaleem. Cross Sectional Analysis of Endodontic Failure in PIMS. *Pakistan Oral & Dental Journal* Vol 28, No. 1; 99-102.
- [12] Chugal NM, Clive JM, Spangberg LS. Endodontic Infection: Some Biologic and Treatment Factors Associated with Outcome. *Oral Surg Oral Med Oral Pathol Oral Radiol Endod* 2003; 96:81-90.
- [13] Col MC Sharma, Maj Gen V Arora, VSM. Determination of Working Length of Root Canal. *MJAFI*, Vol. 66, No. 3, 2010; 231-234.